



PATIENT

BMO Preman

SPECIES

Canine

BREED

Shih Tzu

SEX

Female Spayed

AGE

4 years

WEIGHT

11.69lbs

INTERPRETED BY

Maggie Machen
Lamy, DVM
DACVIM (Cardiology)

IMAGING

PERFORMED BY

Pamela Harrigan,
RDCS

HOSPITAL NAME

Mass Veterinary
Services

REFERRING VET

Dr. Masloski

INVOICE

29182

DATE

2/22/23

PRESENTING CLINICAL SIGNS

History: Recheck echo. History mitral valve dysplasia with LVOTO. Presently, Bmo does have some coughing if she gets excited. She is otherwise doing well with a good appetite and normal activity level. On exam: NSR, grade III/VI murmur with PMI left apical area, PSS, lung fields clear, mm pink, moist, CRT < 2. BP: 110mmHg. Current medications: Atenolol 8mg/ml 0.3mls in the morning *No sedation for study.

-Pertinent previous echo findings (2/15/22 MML): LA 1.7 cm, LA: Ao 1.3; LV 2.1 cm; IVS 0.7 cm; PW 0.7 cm; normal LA size; thickened MV with abnormal motion, no MR; LVOT Vmax 2.1 m/s.

ECHOCARDIOGRAM FINDINGS

2D, m-mode, color flow and Doppler imaging is available.

Left ventricle: The LV diameter is normal with adequate myocardial function. LV wall thicknesses are normal.

Left atrium: The left atrium is normal.

Mitral valve: The anterior leaflet of the mitral valve is significantly thickened with abnormal motion seen in systole. No significant mitral regurgitation.

Aortic valve/aorta: The aortic valve is normal in morphology and mobility. Borderline elevated aortic outflow velocity; laminar flow. No aortic insufficiency.

Right ventricle: Normal right ventricular diameter and morphology indicating no overt evidence of pulmonary arterial hypertension.

Right atrium: Normal RA dimension.

Tricuspid valve: The tricuspid valve appears normal with no tricuspid regurgitation.

Pulmonic valve/pulmonary artery: The pulmonic valve is normal in morphology and mobility. No pulmonic insufficiency. Normal RVOT velocity; laminar flow.

Pericardium/other: No pericardial or pleural effusion noted. No obvious cardiac masses.

Heart rhythm: ECG reveals a sinus rhythm with an average HR of 120bpm.

2-Dimensional Measurements

Ao diam (cm)	1.3
LA diam (cm)	1.6
LA:Ao (Swe)	1.2
IVS thickness (cm)	0.63
LVID diastole (cm)	2.0
PW thickness (cm)	0.64
LVID systole (cm)	1.0
FS (%)	50

Doppler Measurements

PV Vmax (m/s)	0.97
AoV Vmax (m/s)	2.0
MR Vmax (m/s)	NA
TR Vmax (m/s)	NA
TR PG (mmHg)	NA

INTERPRETATION OF THE FINDINGS

Compared to the prior study, findings are consistently stable. The overall dimensions and function are normal with mild LVOT obstruction. This appears hemodynamically insignificant and well controlled on Atenolol. No additional issues are identified.

Given these findings, continue Atenolol lifelong.

Prognosis is open long-term. This patient is still at risk for developing chronic valve changes, which may lead to additional issues in the future. Serial monitoring is advised.



PATIENT

BMO Preman

SPECIES

Canine

BREED

Shih Tzu

SEX

Female Spayed

AGE

4 years

WEIGHT

11.69lbs

INTERPRETED BY

Maggie Machen Lamy, DVM DACVIM (Cardiology)

IMAGING PERFORMED BY

Pamela Harrigan, RDCS

HOSPITAL NAME

Mass Veterinary Services

REFERRING VET

Dr. Masloski

INVOICE

29182

DATE

2/22/23

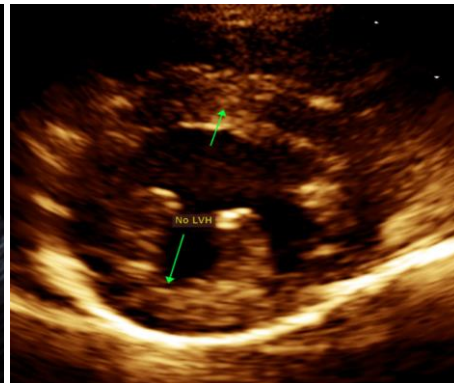
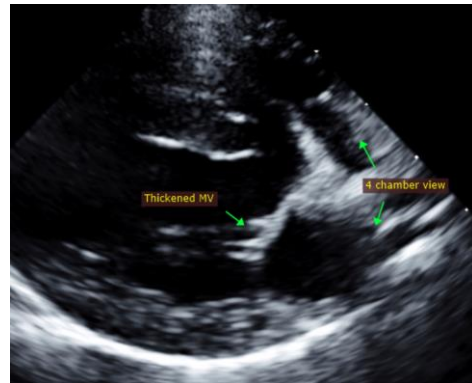
RECOMMENDATIONS

- Continue Atenolol as prescribed.
- Omega fatty acid supplementation and mild salt restriction may be of some long-term benefit.
- Anesthetic risk is considered mild if needed. Cardiac protective drug choices (opioid/benzodiazepine premedication, propofol or alfaxalone induction, isoflurane gas) are recommended. Pre-oxygenate for 5-10 minutes prior to induction. Monitor for arrhythmias, hypotension, and hypoxia both intra and post-operatively and intervene as necessary. Mild IV fluid restriction is recommended to avoid fluid overload. Avoid heart rate stimulating drugs such as atropine unless clinically indicated.
- Monitor for development of a cough, labored breathing, exercise intolerance or collapse episodes.

PLAN

- Recommend conservative monitoring with a recheck echocardiogram annually, sooner if any development of clinical signs.

IMAGES



The information and recommendations provided are based on the images presented by the referring veterinarian. No evaluation can be communicated regarding pathology that was not visible in the image/video clips provided.

Thank you for this referral. This report was generated using transcription software, and minor dictation errors may be present. If the clinical or image interpretation does not parallel your findings or if I can be of any further assistance, please contact me.

Maggie Machen Lamy, DVM
Diplomate of the American College of Veterinary Internal Medicine (Cardiology)
info@sonopath.com

Echocardiogram performed by: Pamela Harrigan, RDCS
Pet Animal Ultrasound Service (4paus.com)